

REHABILITATION OF EDENTULOUS RIDGES WITH LOCATOR OVERDENTURE AND IMPLANT SUPPORTED FIXED DENTAL PROSTHESIS-A CASE REPORT

Rakshith Hegde^{*}, Punit Jain^{}, Nivya John^{***}, Manoj Shetty⁺**

***-Professor, Dept. of Prosthodontics**

**** -PG Student, Dept. of Prosthodontics**

*****-Sr. Lecturer, Dept. of Oral Implantology**

+ -Professor and Head, Dept. of Oral Implantology

A B Shetty Memorial Institute of Dental Sciences, Nitte Deemed to be University, Deralakatte, Mangalore -575018.

Abstract:

Edentulism is poorly received among the young as well as in the old. Various implant supported treatments have not only improves the chewing efficiency but also aids in psycho social well being. Removable implant supported dentures provides good prosthetic outcome with regard to economic and time saving aspects, esthetics and ease of cleanliness. Fixed treatment provides high retention and stability with high predictable outcome. The selection of the treatment depends on factors such as bone quality, interarch distance, patient systemic conditions, cost factor, etc. In this case report we have presented a case with edentulism which was rehabilitated with a locator overdenture and subsequently rehabilitated with implant supported fixed prosthesis.

Keywords: locator, Fixed treatment, Ankylos, Full mouth rehabilitation

Key Message: When removable implant supported dentures provides good prosthetic rehabilitation with regard to economic and time saving standards, fixed treatment provides predictable outcome. Removable implant dentures provide cleaning efficiency and esthetics whereas fixed prosthesis provides retention and stability. The choice between the two depends on the patient expectations and the doctor interpretation of the best possible treatment.

Introduction:

This is the era where people seek a full functional limitless life. Their biological age no longer follows their mental age. People want a well-rounded life may it be at their 20s ,30s or their late 80s and now tooth loss is no longer a barrier .Dental implants have fulfilled this purpose for a few decades now. Various treatments that include removable and fixed options are evolving to benefit various clinical situations.

Implant supported prosthesis has improved patients` ability to look better, eat better and thus live better. Clinical studies have shown better improved life conditions in fixed option than removable treatment options. Although fixed prosthesis shows higher rate of patient acceptance, all clinical scenarios don't allow a fixed option. The patient must be rehabilitated with atleast 4-6 implants for fixed prosthesis ¹ so patients with insufficient bone height or poor quality of bone will have to proceed with removable options such as ball, bar or locator attachments.

Simrahan et al concluded that Locator attachment to be more advantageous to ball and bar systems, regarding the rate of complications in clinical practice.²

In this case report we have presented a treatment of an 82 year old patient with edentulism who had expressed his strong desire for a fixed treatment.

Case History:

An 82 year old male patient reported to the Department of Oral Implantology with a chief complaint of missing upper teeth and lower teeth. On dental examination it was found he was a partially dentate patient with failing existing dentition with a grade III mobility .

On clinical examination it was found that he was in prime of health with no debilitating disorders . Medical investigations such as routine blood checkups ,vital signs were carried out. No medical history was reported that contradicted the implant treatment .

Psychosocial status:the patient was philosophical and expressed a strong desire for a fixed prosthesis.

Diagnosis :

Clinical study models were fabricated and surgical measurements and radiographic examination (panoramic Rx) of maxillary and Mandibular area was done .

Radiological assessment:Pre operative OPG:(Figure 1)On radiographic analysis we found sinus pneumatisation in the maxilla with reduced bone height in the posterior region. The mandible had adequate bone height of 10-11mm anteriorly.

Since we had enough data with the existing study models and xrays a CBCT was avoided.

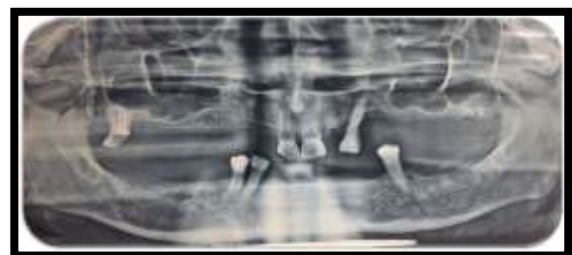

Figure 1 :Preoperative OPG

Treatment planning:

- Extraction of the remaining teeth and immediate implant placement.
- Placement of Ankylos C/X implant (B-8mm) in 35 and 45 region.

(A-9.5mm) in 33 and 43 region,(B-11mm) in 15 region, (B-9.5mm) in 23 region,(A-11mm) in 13 region,(B-11mm) in 25 region.

- Maxillary and Mandibular ridges with metal ceramic prosthesis.
- Patient recall and check up every 6 months

The treatment plan was explained to the patient, and informed consent was obtained thereof as he agreed with the proposed prosthetic solution.

Pharmacological management:

Patient was prescribed antibiotics (Amoxicillin 500 mg) one day before surgery and one hour before surgery as prophylaxis.

Patient would be later advised to continue the antibiotics thrice daily for a week post surgery.

Analgesics(Diclofenac Sodium 50 mg) were also prescribed post treatment. Antibacterial mouth rinse (Chlorhexidinegluconate) was also prescribed.

Case report:**Surgical phase:**

The patient was prepared and sterilized surgical instruments were arranged for the surgery.Extractions were carried out with

respect to maxillary and mandibular anterior teeth under local anaesthesia.(figure 2),(figure 3)The sockets were curetted and irrigated with antibacterial solution(chlorhexidine).

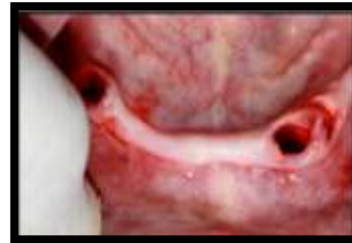

Fig.2 Extraction of mandibular teeth

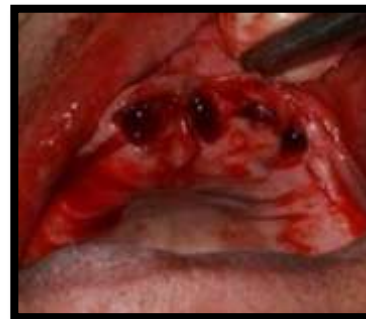

Fig.3.Extraction of maxillary teeth

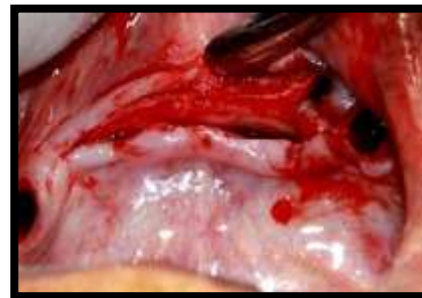
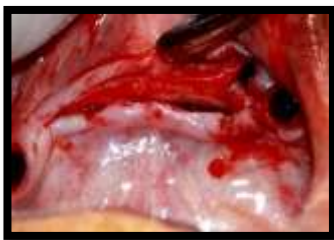
Fig.4. Flap elevation

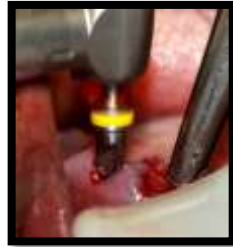Midcrestal incisions were carried out and full thickness flap was elevated(figure 4).Septal bone was removed to ensure flap repositioning and tissue closure in the maxillary region.

Implant osteotomies were carried out with recommended sequence of drills (Ankylos c/x) with copious irrigation. Linderman drill was

used initiate the sequential osteotomy. Trispade drill A & B were used to extend the osteotomy site according to the selection of the implants .(figure 5a &5b) .



5a

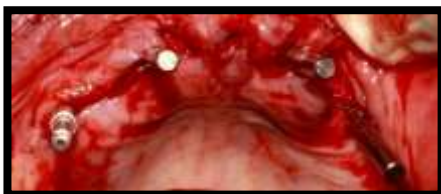


5b

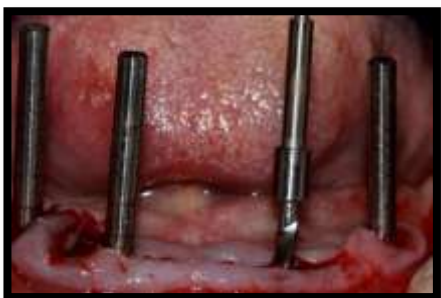Fig.5a: Trispade drill A for Ankylos c/x A implants.

Fig 5b: Trispade drill B for Ankylos c/x B implants

Guide pins were placed in each osteotomy to indicate the direction and ensure parallelism between implant osteotomy sites.(figure 6a &6b).



6a



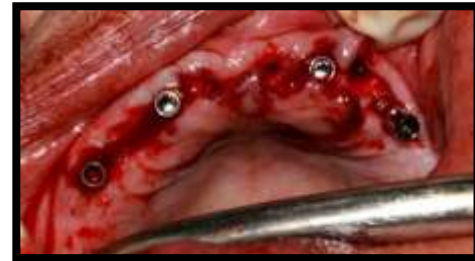6b

Fig 6a: Parallelizing pins placed in the maxillary osteotomies

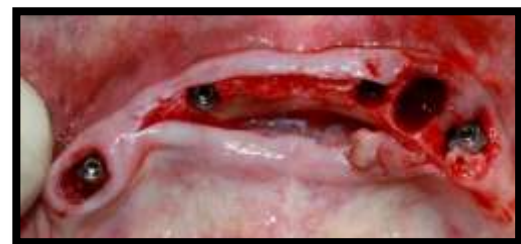Fig 6b: Parallelizing pins placed in the mandibular osteotomies

In the mandibular region, Implants (Ankylos c/x wrt 35,33,43,45) (figure 7a) were placed carefully ,keeping a safe distance from the

mental foramen. In the maxilla Implants (Ankylos c/x wrt 15,13,23,25) were placed at a maximum angulation of 20 degree, avoiding the sinus floor.(figure 7b).



7a



7b

Fig 7a: completion of implant placement in maxilla

Fid 7b: completion of implant placement in mandible

Primary stability of 35 Ncm was achieved. Cover screws were then placed in. Interrupted sutures were placed for primary closure. Immediate post operative OPG was then ordered(Figure 8)

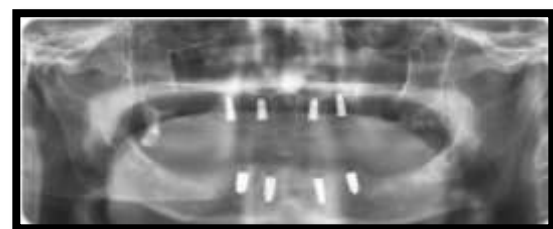


Fig.8 Post operative OPG

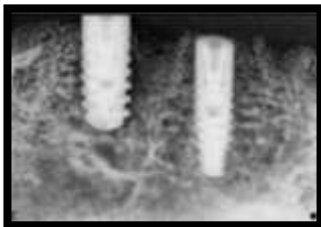
Patient was placed on post operative antibiotic regimen and on analgesics along with instructions on maintenance of oral hygiene and was recalled after one week, one month

and three months, six months and 1 year for follow up.

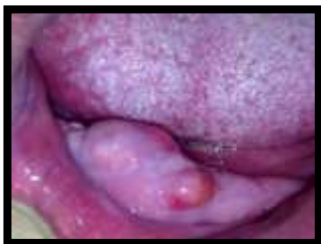Prosthetic phase (three months post implant placement):

Patient was recalled for second stage surgery after three months of implant placement. On radiographic analysis significant crestal bone loss was seen with respect to 45 .(fig 9a)

Cover screws were retrieved non invasively under local anaesthesia.



9a



9b

Fig 9a: implant failure wrt 45 –IOPA

Fig 9b: implant failure wrt 45 –Clinical view

There was failure of the implant placed in the 45 region as suspected (figure 9b). This may be attributed to residual infection in the extraction socket. Implant level impressions were made and casts were poured. (figure 10a & 10 b) .

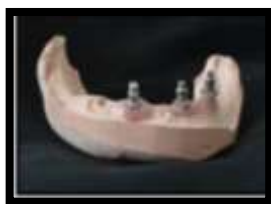
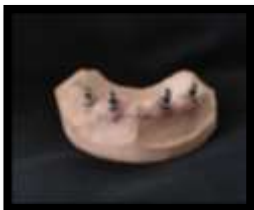
Fig 10a: final casts showing impression post- maxilla

Fig 10b: final casts showing impression post- mandible

Abutments were selected .(regular abutments for the maxillary arch and LOCATOR abutments for the mandibular arch). Maxillomandibular relations were recorded and transferred to a semi adjustable articulator. Trial of the metal framework and the denture was carried out. The maxillary arch was then rehabilitated with implant supported fixed dental prosthesis. A LOCATOR attachment denture was planned for the Mandibular ridge due to the loss of an abutment for the fixed prosthesis. For the delivery of the prosthesis following steps were done . The LOCATOR abutments were screwed in with the driver and block out spacers were placed on the heads of the abutments. Female attachments were positioned with the processing inserts (which will later be replaced with the retentive inserts). The Mandibular denture was ground in the region of the subsequent females so that it could be cemented with cold cure acrylic resin. The denture was then finished and polished. An OPG was then ordered for ensuring proper fit (figure 11)

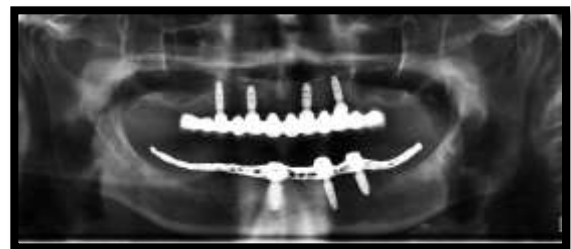


Fig 11: OPG showing locator attachments

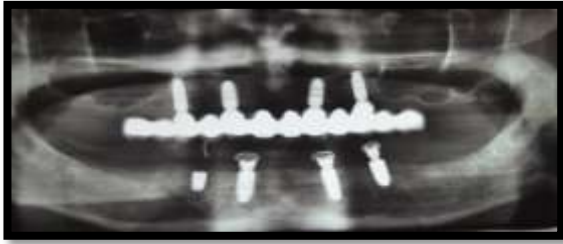


Fig 12: Implant placement in the 45 region-OPG

After three months of wearing removable prosthesis with locator attachment, patient expressed the need for a fixed prosthesis. Ankylos c/x implant was placed in the healed site (45) (figure 12) The patient was then recalled after three months for rehabilitation of the Mandibular ridge with fixed prosthesis. The locator abutments were replaced with regular abutments and implant supported fixed dental prosthesis was cemented in the Mandibular arch.(fig 13 a,13b,13c),

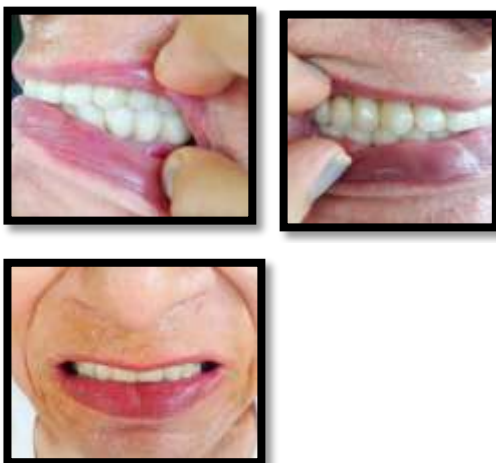

Fig 13 a: left lateral view of the patient (post cementation)

Fig 13 b: right lateral view of the patient (post cementation)

Fig 13 c: facial view of the patient (post cementation)

The 18 month follow up OPG was then taken and sustained level of crestal bone was seen.(figure 14)

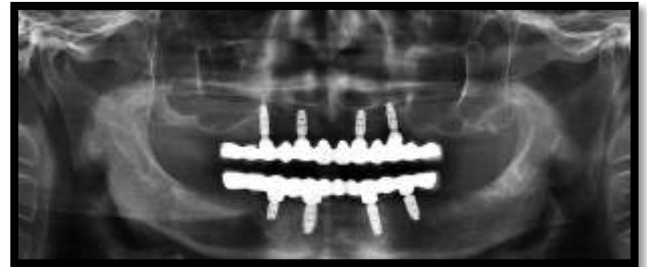


Fig 14: Post cementation of the FDP –OPG

Discussion:

Implant supported overdentures provides retention and good support with the help of the mucosa as well as the implant. Although overdentures have proven to be a successful treatment option which is economic and time saving, multiple pulls of the removable prosthesis can hinder the retentive values of the attachments which would require replacements and multiple visits^{3,4,5}. Fixed prosthesis has shown higher stability, the fixed treatment received a higher rating on the ability to chew.⁶

The most common reason for choosing a dental implant prosthesis was to improve eating ability. Most studies reported improved eating ability after a fixed treatment. Patient tend to report function and chewing ability to be more important than esthetics

In this case, a fixed full mouth rehabilitation was planned so four implants were placed in each arch. Unfortunately the implant in the 45 region failed(extraction placement) . This may be due to the fact that there was remnants of

infective tissue remaining in the extraction socket.^{7,8} Thus a thorough curettage with local antibiotic treatment or planning a different site of implant placement would have been another option. Since we deprived final fixed prosthesis of one abutment support, the patient was treated with locator overdenture. Locators have shown excellent patient compliance with good retentive and resilient properties. Locator attachments are in different colors (clear, pink, blue, green, orange, red) and each has a different retention value.⁹ Since the patient was insistent on fixed treatment we placed a new implant in the region 45 (after 4 months of healing)^{10,11}

Patient was then rehabilitated with fixed shortened dental arch implant supported prosthesis.

While some patients are comfortable with overdentures, some patient expects a more stable retentive option such as a fixed dental prosthesis. Treatment options can vary from person to person, a thorough knowledge of the patient history and also, in this case, the patients expectations will help a practitioner to provide the best possible result.

Further studies have to be conducted so as to provide a reduced time span to rehabilitate the edentulous areas.

REFERENCES:

1) Brånemark P.I., Svensson B, Steenberghe D.V. Ten-year survival rates of fixed prostheses on four or six implants ad modum Brånemark in full edentulism. Clin Oral Implants Res, 1995;6:227-31

- 2) Sirmahan C, Taylan C, Mehmet Y. Complications associated with the ball, bar and Locator attachments for implant-supported overdentures. Med Oral Patol Oral Cir Bucal. 2011 Nov 1;16 (7):e953-9.
- 3) Van Kampen F, Cune M, van der Bilt A, Bosman F. Retention and post insertion maintenance of bar-clip, ball and magnet attachments in mandibular implant overdenture treatment: an in vivo comparison after 3 months of function. Clin Oral Implants Res. 2003; 14:720-6.
- 4) Trakas T, Michalakis K, Kang K, Hirayama H. Attachment systems for implant retained overdentures: a literature review. Implant Dent. 2006;15:24-34.
- 5) Chung KH, Chung CY, Cagna DR, Cronin RJ, Jr. Retention characteristics of attachment systems for implant overdentures. J Prosthodont. 2004;13:221-226.
- 6) Grogono AL, Lancaster DM, Finger IM: Dental implants: A survey of patient's attitudes. J Prosthet Dent .1989;62:573-576
- 7) Kohru, rudek I, wanghl. Immediate Implant placement : positives and negatives: implant dent .19(2):98-108
- 8) Tara L. Aghaloo, Martin Mardirosian and Brando Delgado. Controversies in Implant Surgery. Oral and Maxillofacial Surgery Clinics of North America 29:4, 525-535.
- 9) Evtimovska E, Masri R, Driscoll CF, Romberg E. The change in retentive values of locator attachments and hader clips over time. J Prosthodont. 2009;18:479-83.
- 10) Grossmann Y, Levin L. Success and survival of single dental implants placed in sites of previously failed implants. J Periodontol. 2007;78(9):1670-4
- 11) Alghamdi, A. (2012). Successful treatment of early implant failure: A case

series. Clin Implant Dent Relat Res, 380-7.

implant research, Clin. Oral Impl. Res. 22, 2011 / 1315–1319

12) Attachment systems for implant overdenture: influence of implant inclination on retentive and lateral forces
Tsong-Chieh Yang Yoshinobu Maeda TomoyaGondaSunnyKotecha,clinicaloral

13) LocatorManual:https://www.zestanchors.com/media/wysiwyg/pdf/locator/L8012-TM_REV_D_03-14_tech_manual_only.pdf

Acknowledgement: nil

Conflict of interest declared:nil

Corresponding author: Nivya John,Sr.Lecturer,Dept.of Implantology,A B Shetty Memorial Institute of Dental Sciences,Deralakatte,Mangalore -575018
E-mail –nivijae89@gmail.com

How to cite:Rakshith Hegde,P.Jain,N.John,M.Shetty Rehabilitation of edentulous ridges with locator overdenture and implant supported fixed dental prosthesis-A case report, Annals of Clinical Prosthodontics,vol.2 Issue 1, 6-13